

VEP Optometric Case Study

Missed and Misdiagnosed Retrobulbar Optic Neuritis

ABSTRACT

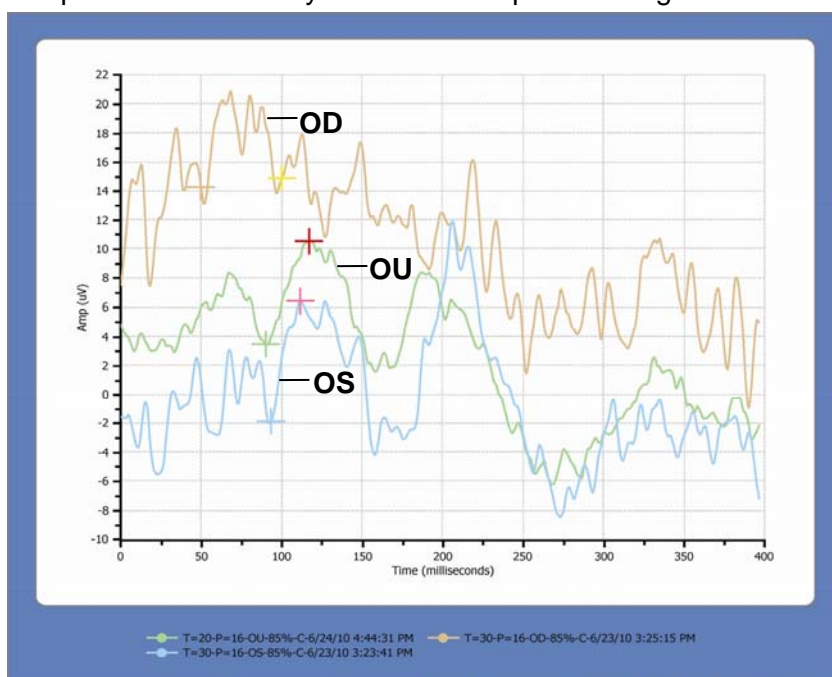
Paula Johnson, OD, FCOVD

INTRODUCTION: A 9 year-old girl was referred to our office by a local optometrist for unexplained decreased vision. She had complained of blurry vision in her right eye for about 3 weeks, which seemed to be affecting her performance in softball.

METHODS: The *Diopsys™ NOVA-TR VEP Vision Testing System* was used to assess the patient’s visual responses for OD, OS, and OU. A good response was obtained OU and OS only. **Fig 1** shows all three recordings. Note the lack of any spike (or depolarization) for the right eye. Additional tests were run and a tentative diagnosis of retrobulbar optic neuritis was made. The patient was referred to a pediatric ophthalmologist for MRI and treatment. The patient was seen by two different ophthalmologists the next day and was diagnosed as “malingering” by both. She was sent home without an MRI. The patient’s mother agreed to allow me to rerun her VEP to see if the results were repeatable.

RESULTS: Based on the recordings from her second visit that showed similar findings to the first, I recommended an MRI of the brain and orbit be done as soon as possible. Results of the MRI confirmed mild edema in the right pre-chiasmatic optic nerve and right side of the optic chiasm. White matter lesions were found in her frontal, temporal, and parietal lobes. The patient was immediately sent to Vanderbilt Children’s Hospital where she was admitted and administered IV antibiotics. Her decreased conduction rate would indicate a problem along the neural pathway and supports her diagnosis of “Developing Multiple Sclerosis.”

This case exemplifies the reliability and efficacy of VEP results and their importance in the clinical decision-making process.



	T=20-P=16-OU-85%-C-6/24/10 4:44:31 PM	T=30-P=16-OD-85%-C-6/23/10 3:25:15 PM	T=30-P=16-OS-85%-C-6/23/10 3:23:41 PM
Left Cursor	90.00 ms	50.00 ms	93.33 ms
Right Cursor	3.45 uV	14.2 uV	-1.8 uV
	116.6 ms	100.0 ms	111.6 ms
	10.4 uV	14.8 uV	6.44 uV
Delta	26.66 ms	50.00 ms	18.33 ms
	7.02 uV	0.60 uV	8.33 uV
Eye	OU	OD	OS
CheckSize	16	16	16
Test Time	20	30	30
Contrast	85	85	85
Pattern	Checkerboard	Checkerboard	Checkerboard
Binasal	N	N	N
Correction	N	N	N

Figure 1

VEP Optometric Case Study

Missed and Misdiagnosed Retrobulbar Optic Neuritis

Paula Johnson, OD, FCOVD

Presentation: A precocious, 9 year-old girl was referred to our office by a local optometrist for unexplained decreased vision. She had complaints of blurry vision in her right eye for about 3 weeks, which seemed to be affecting her performance in softball. Medical history was unremarkable, and she was not taking any medications. She had no previously reported vision problems and had never worn glasses. Records from the referring optometrist showed best corrected acuities of 20/80 OD and 20/40 OS with minimal refractive error and good ocular health.

Assessment: Entering unaided distant acuities were Finger Count at 2ft OD and 20/30 OS representing a large decline in OD vision over a 2 week period from her previous optometric appointment. Motilities were full and cover test in all 9 gazes was orthophoric. Pupils were equal, round, reactive, and no apparent APD was present. Stereopsis was reduced to 200 sec arc and confrontations were unable to be obtained. Refraction was OD PL, OS +0.25sph with no improvement in acuities in either eye. Pressures were 12mmHg OD, and 10mmHg OS. Dilated fundus examination revealed symmetric CD ratios of .25/.25 OU. Optic nerves appeared well perfused and without edema. Macula, vessels, posterior pole, and periphery of both eyes were unremarkable.

VEP testing was done beginning with the 16 check size. A good response was obtained OU and OS only. **Fig 1** shows the initial recorded waveforms for OD, OS, and OU at 16 check size. Note the lack of any spike (or depolarization) for the right eye.

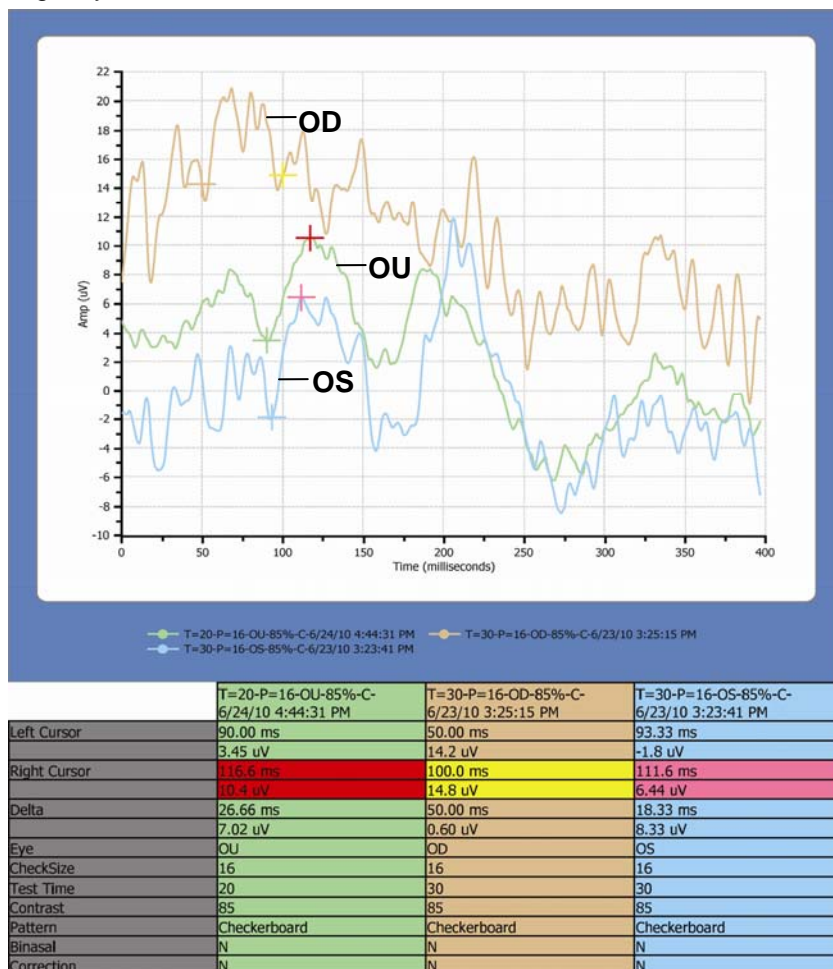


Figure 1

VEP Optometric Case Study (cont.)

The test was then repeated on the right eye only with increasing check sizes of 8 and 4. **Fig 2** is a series of OD readings at 16, 8, and 4 check sizes (the smaller the number, the larger the visual stimulus). Note that the first VEP response does not occur until reaching the second largest visual stimuli.

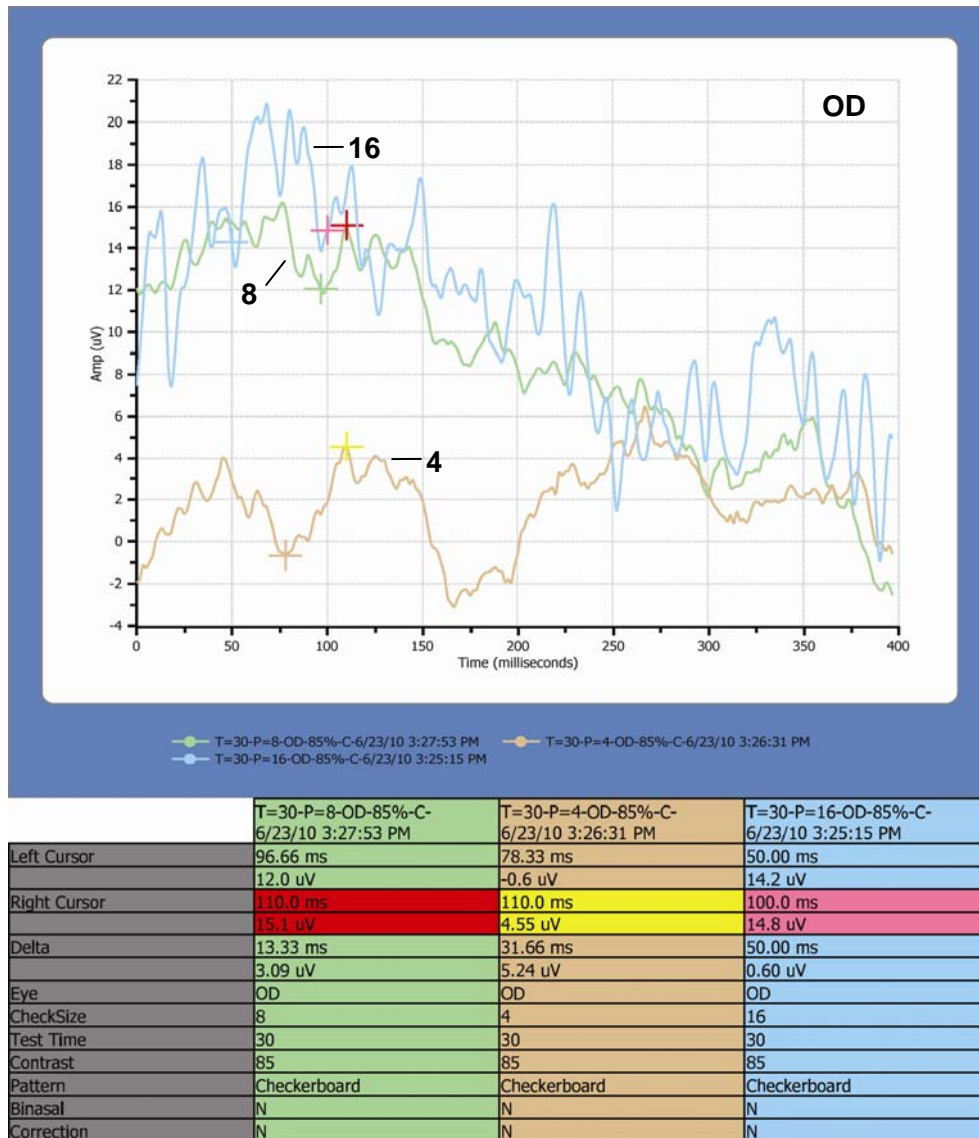


Figure 2

Diagnosis and Treatment:

Based on the patient's subjective responses, correlating objective VEP testing results, and unremarkable ocular appearance, a tentative diagnosis of retrobulbar optic neuritis was made. The patient was referred to a pediatric ophthalmologist for MRI and treatment. Due to her large decline in vision OD in such a short period of time, she was seen the following morning for evaluation. The patient was then diagnosed as "malingering" by two different doctors that day and was sent home without an MRI.

VEP Optometric Case Study (cont.)

The patient's mother agreed to allow me to re-evaluate the patient and rerun her VEP to see if the results were repeatable. **FIG 3** shows the results of that test. Again, no VEP waveform was obtained until reaching a check size of 8. In addition, both the latency and delta values were very similar to the previous day's testing.

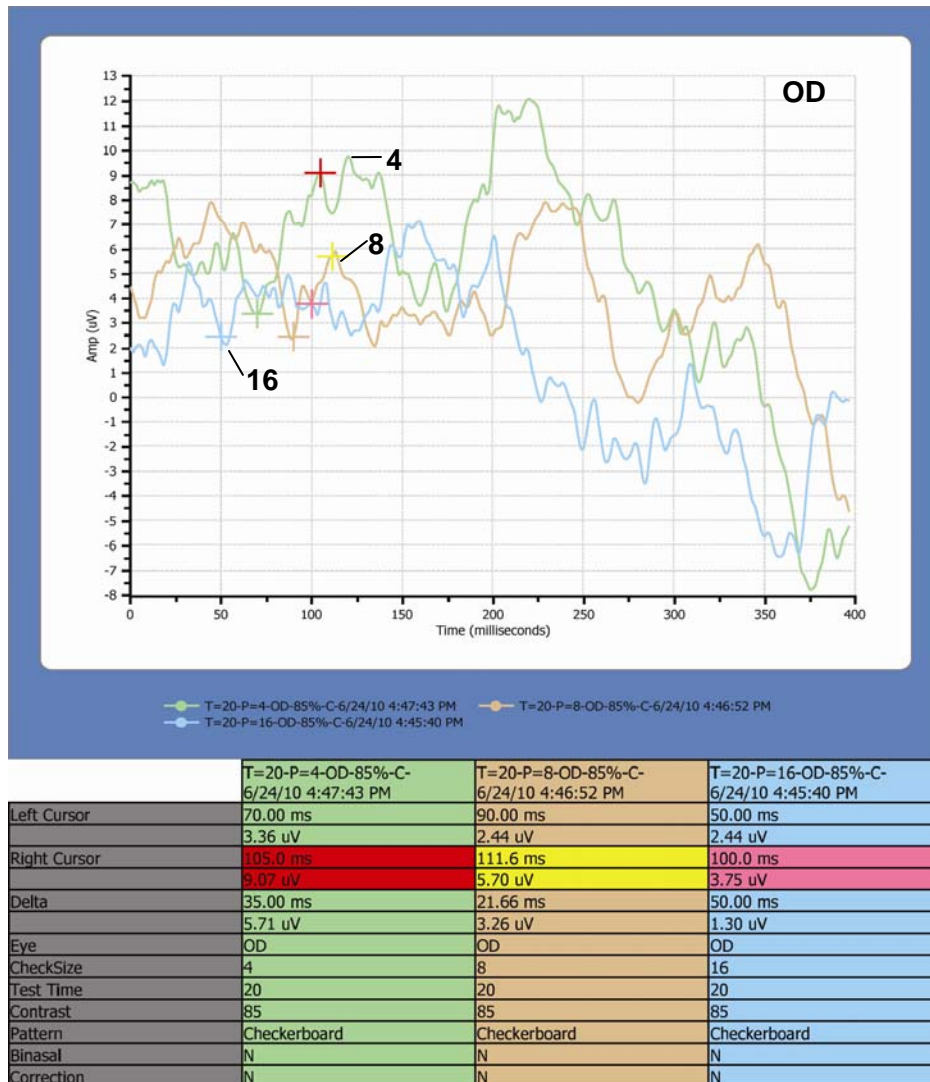


Figure 3

I recommended an MRI of the brain and orbit be done as soon as possible. Results of the MRI confirmed mild edema in the right pre-chiasmatic optic nerve and right side of the optic chiasm. White matter lesions were found in her frontal, temporal, and parietal lobes, more pronounced on the right side consistent with a demyelinating disease.

The patient was immediately sent to Vanderbilt Children's hospital where she was admitted and administered IV antibiotics. A team of doctors was assigned to her to find an etiology for her symptoms.

She was released 1 week later after completing IV steroid treatments. Her diagnosis has since been updated to "Developing Multiple Sclerosis." She continues to be followed and regular MRIs are performed.

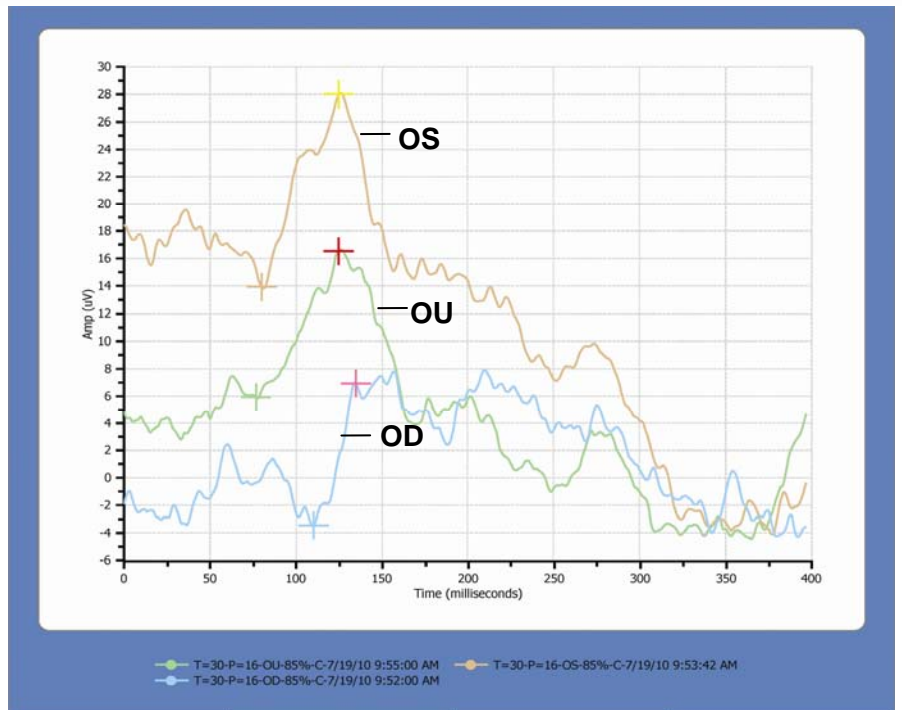
The patient returned for a 1 month follow-up after IV steroid treatment. Her acuities had improved to 20/40 OD, and 20/20-1 OS. Ocular health still appeared normal OU and confrontations were full OD and OS. Intraocular pressures were 15 and 12mmHg respectively.

VEP Optometric Case Study (cont.)

VEP testing was repeated and good response was elicited with a 16 check size in both her right and left eyes. **FIG 4** shows the results from that follow-up. Also of note is her greatly increased latency (135ms). Latency measures the speed at which an action potential reaches the visual cortex. Her decreased conduction rate would indicate a problem along the neural pathway and support the diagnosis of optic neuritis and MS.

Summary: This case exemplifies the reliability and efficacy of VEP results and their importance in the clinical decision-making process. Multiple aspects of the VEP results were clinically significant:

- Amplitude of the VEP waveform correlates with visual discrimination
- General appearance of the waveform can be indicative of the point at which there is no cortical response to the visual stimuli
- Increased latency measurement can be indicative of decreased neural pathway function



	T=30-P=16-OU-85%-C-7/19/10 9:55:00 AM	T=30-P=16-OS-85%-C-7/19/10 9:53:42 AM	T=30-P=16-OD-85%-C-7/19/10 9:52:00 AM
Left Cursor	76.66 ms	80.00 ms	110.0 ms
Right Cursor	5.91 uV	13.9 uV	-3.4 uV
Delta	48.33 ms	45.00 ms	25.00 ms
Eye	OU	OS	OD
CheckSize	16	16	16
Test Time	30	30	30
Contrast	85	85	85
Pattern	Checkerboard	Checkerboard	Checkerboard
Binasal	N	N	N
Correction	Y	Y	Y

Figure 4

When working with children, it is vital for optometrists to have objective means of testing, as often subjective responses can be misunderstood. The VEP is an excellent tool to accurately measure a child's visual response. A child may be able to fool an unsuspecting doctor, but not a VEP test.

About the Author: Dr. Paula Johnson's practice, Johnson Vision Development Center in Jackson, TN, is dedicated to the diagnosis and treatment of binocular vision disorders and neuro-vision processing deficits. She is a board member of the Therapy and Learning Center, a program that provides multidisciplinary quality care to special needs children in the West Tennessee area. She is a fellow of the College of Optometrists in Vision Development, and a member of the Optometric Extension Program, the Tennessee Optometric Association, and the American Optometric Association.

For more information on the



please call Matt Emmer at 973-244-0622 or email memmer@diopsys.com